

PATIENT

Ares Currie

SPECIES

Canine

BREED

Pitbull

SEX

Male Neutered

AGE

9 years

WEIGHT

75lbs

INTERPRETED BY

Maggie Machen Lamy,
DVM, DACVIM
(Cardiology)

IMAGING PERFORMED BY

S. Barthelemy, DVM

HOSPITAL NAME

Canyon Meadows
Veterinary Clinic

REFERRING VET

Dr. Leboldus

INVOICE

29513

DATE

3/9/23

PRESENTING CLINICAL SIGNS

History: Grade 3/6 heart murmur. Presented for bloody discharge from nose. Labs show progressive regenerative anemia and leukocytosis with marked ALP elevation.
-Abnormal PE/Chem/CBC/UA Results: Regenerative anemia - Hct 30%. Mild neutrophilia and monocytosis. Marked ALP elevation over 2000.

ECHOCARDIOGRAM FINDINGS

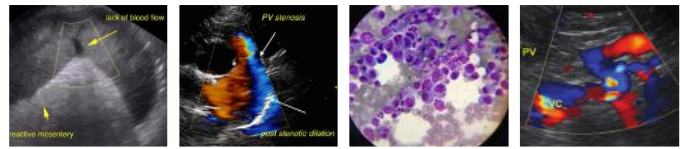
2D, m-mode, color flow and doppler imaging is available. Mild mitral valve leaflet thickening with no obvious prolapse into the left atrial lumen. Trace mitral regurgitation is identified. Normal left atrial dimension. Normal LV diameter with normal myocardial function. The tricuspid valve appears subjectively normal. No TR. The right heart is normal. No overt evidence of pulmonary arterial hypertension. The pulmonic and aortic valves are normal in morphology and mobility. No aortic abnormalities identified, with normal outflow velocity. Normal pulmonic outflow velocities. No aortic insufficiency. No pulmonic insufficiency. No pericardial or pleural effusion noted. No cardiac tumors observed.

CARDIAC CHART

CANINE CARDIAC PARAMETERS	MR VMAX (m/s)	TR VMAX (m/s)	LA/AO (Boon method)	LA/AO (Heart Base; Swe)	FS (%)	EF (%)	EPSS (cm)
NORMAL PARAMETER	4.5-5.5	<2.7	1.3	<1.6	28-40	40-100	<0.6
PATIENT	NM	NA	1.3	1.2	46	77	0.7
CANINE CARDIAC PARAMETERS	HR (BPM)	AV VMAX (m/s)	PV MAX (m/s)	BODY WEIGHT (kg)	LA 2D short axis Base view (cm)	LVIDd Avg: 2D and m-mode short axis (cm)	LVIDs Avg: 2D and m-mode short axis (cm)
NORMAL PARAMETER	50-100	0.7-1.7	0.7-1.6	BELOW	BELOW	BELOW	BELOW
PATIENT	43	1.5	1.1	34.0	3.0	4.9	2.6
*Normal chamber parameters expressed as a mean value (SD)				3	1.27 (5.3)	2.46 (2.46)	1.36 (5.5)
BODY WEIGHT DEPENDENT PARAMETERS				5	1.40 (4.5)	2.74 (5.2)	1.60 (4.7)
<i>*Note: All measurements based upon multi-modal images and methods. An average value is reported.</i>				10	1.50 (3.8)	3.27 (3.5)	2.06 (3.1)
				15	1.83 (2.0)	3.71 (2.4)	2.43 (2.1)
				20	2.02 (1.9)	4.14 (2.2)	2.80 (2.0)
				25	2.18 (2.4)	4.48 (2.9)	3.10 (2.5)
				30	2.33 (3.3)	4.83 (3.9)	3.39 (3.4)
				35	2.48 (4.3)	5.17 (5.0)	3.69 (4.5)
				40	2.62 (5.2)	5.48 (6.1)	3.96 (5.4)
				50	2.88 (7.1)	6.07 (8.3)	4.46 (7.4)

INTERPRETATION OF THE FINDINGS & FURTHER RECOMMENDATIONS

Overtly normal cardiac structure and function with no cause of a murmur identified. Trace MR is noted, which may suggest early valve disease and should be monitored for progression. No other significant valvular insufficiencies were noted and no structural issues identified. In a patient with anemia, this is the likely cause resulting in a physiologic flow murmur not appreciated here. It is reasonable to monitor periodically via recheck echocardiography in the future, particularly should the murmur persist/progress.



PATIENT

Ares Currie

No cardiac medications are indicated at this time. Monitor for any development of cough, labored breathing or exercise intolerance.

SPECIES

Canine

No cardiac contraindication for general anesthesia.

Recommend recheck echocardiogram in 12-18 months to screen for progression or development of concurrent cardiac disease that the preexisting murmur may mask.

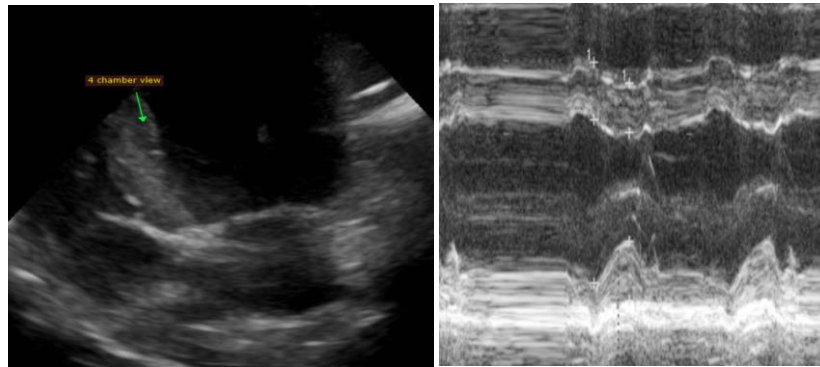
BREED

Pitbull

IMAGES

SEX

Male Neutered



AGE

9 years

WEIGHT

75lbs

The information and recommendations provided are based on the images presented by the referring veterinarian. No evaluation can be communicated regarding pathology that was not visible in the image/video clips provided.

INTERPRETED BY

Maggie Machen Lamy,
DVM, DACVIM
(Cardiology)

Thank you for this referral. This report was generated using transcription software, and minor dictation errors may be present. If the clinical or image interpretation does not parallel your findings or if I can be of any further assistance, please contact me.

Maggie Machen Lamy, DVM
Diplomate of the American College of Veterinary Internal Medicine (Cardiology)
info@sonopath.com

IMAGING PERFORMED BY

S. Barthelemy, DVM

HOSPITAL NAME

Canyon Meadows
Veterinary Clinic

REFERRING VET

Dr. Leboldus

INVOICE

29513

DATE

3/9/23